

Original Paper

## Pain: An Evidence-Based Approach Through the Auricular Acupuncture Microsystem

Nader Soliman, MD

### ABSTRACT

The auricular acupuncture microsystem has been clinically proven to be an effective tool for the treatment of both acute and chronic pain. The auricular acupuncture microsystem provides a clear mapping of all the body organs and structures including that of the various brain structures. Some of the brain structures known to be involved in pain perception and pain modulation can be directly treated through their projection sites on the ear.

**Key Words:** Pain, Pain Modulation Centers, Autonomic Nervous System, Auricular Therapy

### INTRODUCTION

THE INTERNATIONAL ASSOCIATION for the Study of Pain (IASP) defines pain as “an unpleasant sensory and emotional experience that is associated with actual or potential tissue damage or described in terms of such damage.”<sup>1</sup> Pain is a universal human experience that ranges from mild discomfort to an agonizing feeling. It may be localized in certain areas of the body or generalized and diffuse. Generally, pain serves as a warning signal indicating the presence of disease or tissue damage. The stimulation of nerve endings results in the physical components of pain. Specific nerve fibers and pathways are responsible for mediating the pain sensation to various parts of the brain, where conscious appreciation of pain signals is modified. Acute pain is frequently associated with anxiety and emotional distress and is regarded as a biological response to injury, surgical procedures, or illnesses. Acute pain is expected to dissipate once the underlying cause is treated. Failure to address the acute stages of pain may lead to the progression of chronic pain.

Typically, chronic pain is experienced by patients beyond the expected time of healing of the underlying etiological condition. Chronic pain may be experienced as either intermittent or continuous pain.

Chronic pain has long been a puzzle that lacked resolution in the majority of cases. Contrary to acute pain, chronic pain does not seem to serve any apparent biological function and frequently is associated with depression, sleep disturbance, and fatigue, among other sequelae. Often, various medical approaches fail to adequately address chronic pain. Somatogenic pain is caused by organic diseases and is usually divided into nociceptive pain and neuropathic pain. Nociceptive pain results from the stimulation of the nociceptors (pain-sensitive receptors' nerve endings) found in the skin, muscles, joints, and internal organs. Conversely, neuropathic pain results from pathology involving either the central nervous system or the peripheral nervous system. Pathological conditions associated with neuropathic pain include spinal cord injury, stroke, or diabetes mellitus, among others. Cancer may incite pain that is both nociceptive and

neuropathic in nature. Psychogenic pain is frequently described as pain of variable intensity with no clearly identifiable cause. Although many patients with psychogenic pain are frequently considered malingering, in many cases, the patients are genuinely experiencing pain of undetermined etiology.

Nociceptive receptors are generally initiated by stimuli such as trauma, inflammation, exposure to toxic substances, and other similar detrimental stimuli. Such information is conveyed to the dorsal horn cells of the spinal cord via the peripheral nerves. The dorsal horn cells, depending on the etiological factor, may incite actions to protect the individual or modulate the pain signal before reaching the higher brain centers. The process of modulation may, in fact, either reinforce or diminish the pain signal. Many brain structures are also involved in the process of modulating the pain sensations, which helps explain the complexity of the pain process. Pain information reaches the thalamus via the spinal cord. The thalamus is responsible for communicating with 3 other brain structures: the somatosensory cortex, which is responsible for the interpretation of the pain signals received; the limbic system, which is responsible for the regulation of the emotional response to the pain signals; and the frontal cortex, which handles the thought process. The brain's response includes the release of serotonin, endorphins, and enkephalin that help dampen the intensity of pain. Culture, ethnicity, family situation, and sex may modify both the emotional and cognitive response to pain.

## AURICULAR TREATMENT

In the 1960s, Nogier's auricular system evolved to a Three-Phase system. These phases are reflective of acute pathology (Phase 1), chronic degenerative pathology (Phase 2), and chronic non-degenerative pathology (Phase 3). The Three-Phase auricular system provides 3 possible projection sites for each organ and structure depending on the intensity and the chronicity of the pathology. This enables more precise and effective treatment of any pathological condition. Recent studies about the ability of the brain to store information strongly suggest that memory is stored in the brain in a holographic pattern.<sup>2</sup> The theory suggests that memory is not localized but stored all over the brain. This reflects the ability of certain functions to be taken over by other parts of the brain once the original sites are afflicted by pathology. As a correspondence system, the ear echoes the same changes. Such changes are responsible for the multiple auricular projection sites of various organs and structures.<sup>3</sup>

Pain management through Three-Phase auricular therapy is often effective and occasionally miraculous. For many years, I have been using this method of therapy to treat pain of various etiologies with considerable success. Various studies have documented the efficacy of auricular therapy in combating pain. In a study by Alimi et al,<sup>4</sup> the authors

observed reduction in pain intensity and a clear benefit from auricular acupuncture for cancer patients with pain, despite stable analgesic treatment. Niemtzwow<sup>5</sup> reported considerable attenuation of body pain addressing the cingulate gyrus, the Point Zero, and the Shenmen point among other auricular points. Essentially, these 3 points are the auricular projection sites of the cingulate gyrus in all 3 auricular phases.<sup>3</sup>

An initial traditional medical evaluation is necessary for proper understanding of the extent of the pathology. An evaluation to identify the presence of possible energetic blockages is essential prior to any successful auricular treatment. Nogier identified many of these blockages that are described as localized disturbed energetic foci within the living system that tend to lead to major energetic disturbances. Energetic blockages can hinder both diagnosis and treatment.<sup>3</sup> Failure to identify such blockages could render any conventional or alternative treatment ineffective.<sup>6</sup> The most commonly encountered energetic blockages may be identified at the projection sites of the corpus callosum, the pineal gland, and the area of the posterior interhemispheric fibers that is known as the R zone (Figure 1).

Emotional blockages identified by Nogier were identified by scientific studies to play an important role in pain modulation. In 2006, a study by Geha et al found that patients with chronic regional pain syndrome (CRPS) exhibited a significant decrease in regional white matter mainly in the prefrontal tracts and the corpus callosum.<sup>7</sup> The R zone is part of the callosal radiation and is identified in the posterior commissural fibers and the hippocampal commissural fibers. Ploghaus et al<sup>8</sup> identified the hippocampal formation and parahippocampal gyrus regions to be the most active brain areas during mismatch between the expectation and the delivery of painful stimulation. Since the R zone is part of the hippocampal formation, it is expected to play an important part in pain perception and control. The findings of a study by Targut et al<sup>9</sup> suggest that there is a significant interaction between pineal gland calcification and lumbar intervertebral disk degeneration. In 1992, Sandyk<sup>10</sup> demonstrated that the successful treatment of a patient with an acute migraine attack with external magnetic fields, which acutely inhibit melatonin secretion in animals and humans, attests to the importance of the pineal gland in the pathogenesis of migraine headache.

Scanning the projection sites of these structures in all 3 phases utilizing an electrical point finder can help identify the presence of energetic blockages at these sites. Additional possible energetic blockages include chronic sinusitis, dental foci, amalgam and other metal toxicity, chronic appendicitis, scars, malignancy, sacroiliac joint dysfunction, temporomandibular joint dysfunction, vertebral subluxation, and first rib syndrome. These additional blockages may be easily identified from the patient's history in most cases. If such a blockage is suspected, the auricular projection sites of these blockages must be scanned for activity and treated as necessary. Once energetic blockages are ruled out or tem-

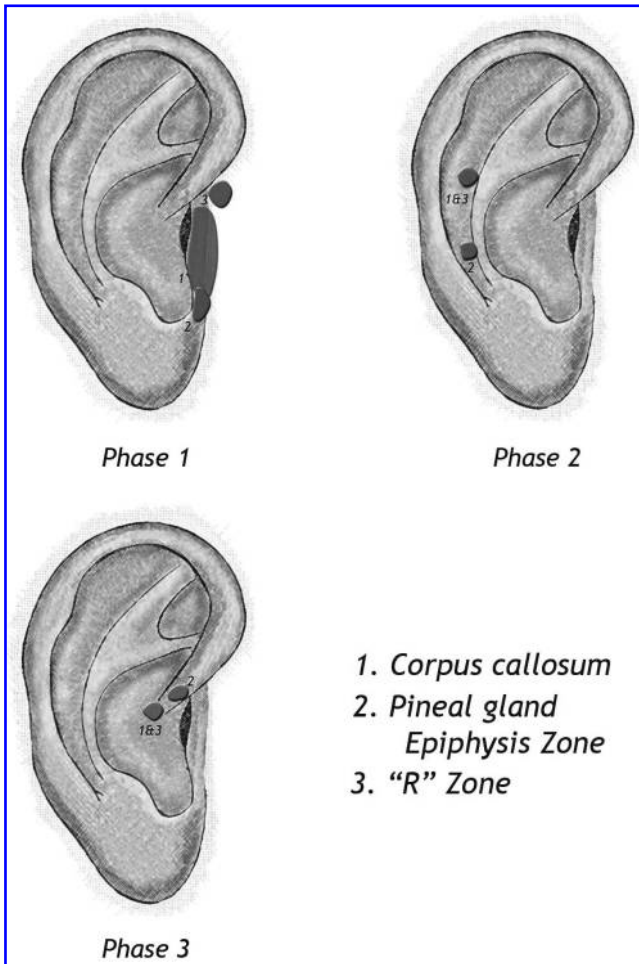


FIG. 1. Emotional Blockages Treatment Zones

porarily treated if present, the evaluation of the possible projection sites of the involved structures should follow. The projection sites of the injured or painful organ or structure should be examined for tenderness and electrical activity.

The patient's history should alert the clinician of the possible involved phases. A painful knee resulting from a minor trauma during a soccer game of 1-day duration with a normal x-ray result will call for exploring the knee projection site in Phase 1. Chronic hip pain of many months' duration with investigations excluding any cartilaginous damage should direct the clinician to explore both Phase 1 and Phase 3. Conversely, a patient with known cartilaginous damage to the shoulder joint is expected to have an active zone corresponding to Phase 2 in addition to those in Phase 1 and Phase 3. Activity in multiple phases is expected since patients experiencing chronic pain also experience persistent acute pain or periodic acute exacerbation of their pain.

Auricular treatment of pain in any particular body region should also involve the exploration of the corresponding bones and nerves in addition to the evaluation of the soft tissues involved. For example, pain in the chest wall would

call for the exploration of the projection sites of the ribs and the intercostal muscles in the suspected phases. Exploration of the projection sites of the overlying skin is also recommended. In addition, the corresponding nerves should be evaluated at their projection sites in connection with the spinal cord in the proper phases. Because of the role of the autonomic nervous system in influencing the duration and the intensity of pain, clinicians should consider exploring the corresponding area of the sympathetic chain in the appropriate phases for electrical activity. Finally, pain-modulating centers should be systematically explored and treated when active.<sup>3</sup>

**PAIN-MODULATING CENTERS**

Recent clinical studies have identified the presence of pain-modulation centers in the brain. In all cases of pain, and particularly in chronic pain conditions that are labeled as catastrophic such as fibromyalgia syndrome and CRPS (previously known as reflex sympathetic dystrophy), these

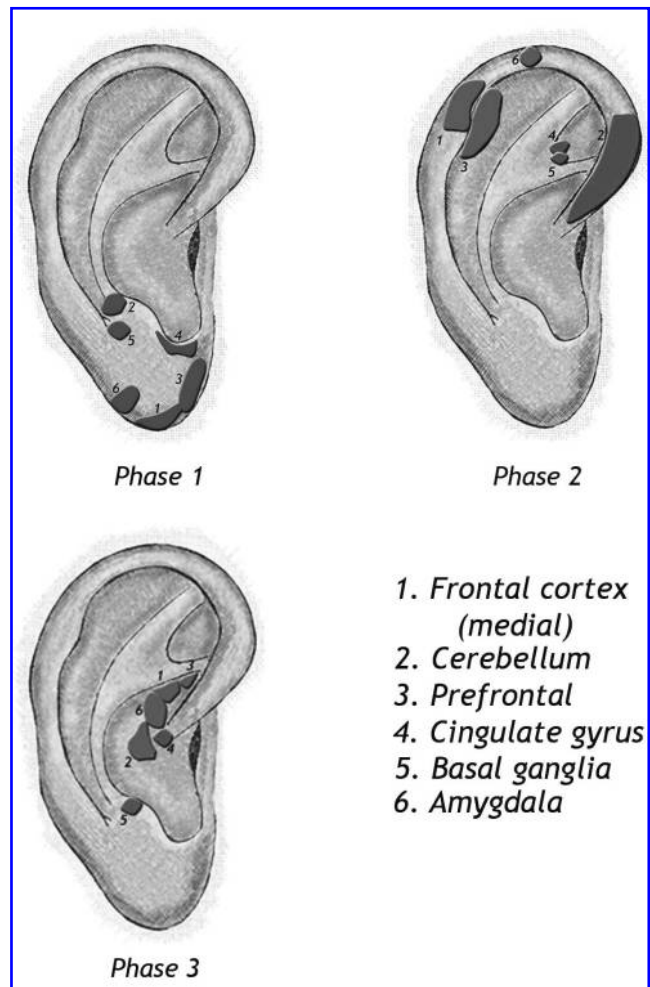


FIG. 2. Pain-Modulation Centers

higher brain centers should be thoroughly explored for activities and treated as necessary. Pain perception is distorted through altering the attention and the anticipation of pain coupled with heightened emotional response to it.<sup>11</sup> Central pain-modifying centers are typically divided into 3 categories: the pain attention centers, the pain anticipation centers, and the emotional modulation pain centers.

### Pain Attention Centers

These centers involve the prefrontal cortex and the anterior cingulate cortex. The projection sites of these structures should be explored in all Three Phases and treated if active (Figure 2). Studies have shown a decreased volume of the prefrontal cortex that is directly related to the duration of pain.<sup>12</sup> The prefrontal cortex is involved in pain perception, memory, decision-making, planning, and rational thoughts. Atrophy of this area can explain the overtly emotional response to pain in patients with chronic pain and their inability to deal with the situation. The prefrontal cortex also exhibits decreased levels of the neurotransmitter *N*-acetylaspartate that may be considered a marker for cell density in the brain, denoting irreversible changes.<sup>12</sup> The cingulate gyrus in Phase 2 is projected near the apex of the triangular fossa near the area known as the Shenmen Zone in Chinese ear charts, while in Phase 3, it is projected onto the site of the Zero Zone.<sup>3,13</sup> Recent medical studies have shown that the anterior cingulate cortex in the human brain has considerable influence on the relief of intractable pain. Positron emission tomography (PET) studies consistently report metabolic activation of the cingulate gyrus as a result of painful stimuli. Lesions of the cingulate cortex produced relief from chronic pain in 23%<sup>14</sup> and in 75% of patients.<sup>15</sup> The cingulate gyrus is essentially responsible for the coordination of sensory input with emotions, the emotional responses to pain, and the regulation of aggressive behavior.<sup>16,17</sup>

### Pain Anticipation Centers

Studies have shown that catastrophic pain is associated with increased activities in brain areas related to the anticipation of pain. These centers include the frontal cortex and the cerebellum (Figure 2). The cerebellum appears to play a fundamental role in pain-related behavior. Anticipation of pain can, in its own right, cause mood changes and behavioral adaptations that exacerbate the suffering experienced by patients with chronic pain. Selective manipulations of activity at these sites may offer therapeutic possibilities for treating chronic pain.<sup>6,18</sup>

### Emotional Modulation Pain Centers

These centers include the claustrum (basal ganglia) and the amygdala (Figure 2). Neugebauer found that the amygdala appears to play a dual facilitatory and inhibitory role in the modulation of pain behavior and nociceptive pro-

cessing at different levels of the pain neuroaxis.<sup>18,19</sup> Chudler and Dong<sup>16</sup> indicated that most studies agree that some neurons within the basal ganglia encode the stimulus intensity. However, these neurons do not appear to encode stimulus location since the receptive fields of these cells are large. Many basal ganglia neurons responsive to somatosensory stimulation are activated exclusively or differentially by noxious stimulation.<sup>16</sup>

## DISCUSSION

Familiarity with the accurate projection sites of the various brain structures on the auricle is necessary for the proper approach to pain management through auricular therapy. Following the above-mentioned standard strategy to combat pain offers a sophisticated approach utilizing the auricular acupuncture microsystem.<sup>3</sup> Addressing energetic blockages is considered the first step toward achieving this goal. Energetic blockages must be treated at the beginning of every session until they are completely eliminated. Next, auricular therapy techniques should be used to correct the energetic imbalance in organs and structures afflicted by pain together with the corresponding nerve supply, both somatic and autonomic. Finally, the pain-modulation centers recently identified through various clinical studies should be explored for electrical activity and treated if active.

Understanding that all these organs and structures are projected onto the ear in 3 different phases is essential for obtaining superior results. While most acute pain conditions are expected to respond to treatment of Phase 1 (inverted fetus presentation), chronic pain conditions are likely to require the addition of Phase 3 and occasionally Phase 2. Exploring the 3 projection sites of the involved structures for electrical activity will identify the phase or phases in need of treatment.

## CONCLUSIONS

The auricular acupuncture microsystem offers clear and defined projection sites of all organs and structures, including those brain structures involved in pain modulation. Accordingly, addressing pain through the auricular acupuncture microsystem may offer a superior approach to pain problems regardless of their intensity and duration.

## REFERENCES

1. International Association for the Study of Pain Web site. IASP terminology. <http://www.iasp-pain.org/AM/Template.cfm?Section=Home&template=/CM/HTMLDisplay.cfm&ContentID=6648>. Accessed July 25, 2008.

2. van Heerden P. Models for the brain. *Nature*. 1970;227:410–411.
3. Soliman N. *Soliman's Auricular Therapy Textbook*. Bloomington, IN: Authorhouse; 2008.
4. Alimi, D. Rubino C, Pichard-Léandri E, et al. Analgesic effect of auricular acupuncture for cancer pain: a randomized, blinded, controlled trial. *J Clin Oncol*. 2003;21(22):4120–4126.
5. Niemtzow R. Battlefield acupuncture. *Medical Acupuncture*. 2007;19(4):225–228.
6. Rapoport M, van Reekum R, Mayberg H. The role of the cerebellum in cognition and behavior: a selective review. *J Neuropsychiatry Clin Neurosci*. 2000;12(2):193–198.
7. Geha PY, Baliki MN, Chialvo DR, Harden R. Multidisciplinary pain abstracts. *Pain Practice*. 2007;7(2):208.
8. Ploghaus A, Tracey I, Clare S, et al. Learning about pain: the neural substrate of the prediction error for aversive events. *Proc Natl Acad Sci U S A*. 2000;97(16):9281–9286.
9. Targut AT, Sonmez I, Cakit BD, Kosar P, Kosar U. Pineal gland calcification, lumbar intervertebral disc degeneration and abdominal aorta calcifying atherosclerosis correlate in low back pain subjects: a cross-sectional observational CT study. *Pathophysiology*. 2008;15(1):31–39.
10. Sandyk R. The influence of the pineal gland on migraine and cluster headaches and effects of treatment with picoTesla magnetic fields. *Int J Neurosci*. 1992;67(1–4):145–171.
11. Gazzeri R, Mercuri S, Galarza M. Atypical trigeminal neuralgia associated with tongue piercing. *JAMA*. 2006;296(15):1840–1841.
12. Apkarian AV, Sosa Y, Sonty S, et al. Chronic back pain is associated with decreased prefrontal and thalamic gray matter density. *J Neurosci*. 2004;24(46):10410–10415.
13. Soliman N. *Soliman's Atlas of Auricular Therapy*. Rockville, MD: Alternative Medicine Publishers; 2006.
14. Hurt RW, Ballantine HT. Stereotactic anterior cingulate lesions for persistent pain: a report of 68 cases. *Clin Neurosurg*. 1973;21:334–351.
15. Folz EL, White LE. Pain “relief” by frontal cingulotomy. *J Neurosurg*. 1962;19:89–100.
16. Chudler EH, Dong WK. The role of the basal ganglia in nociception and pain. *Pain*. 1995;60(1):3–38.
17. Gracely RH, et al. Pain catastrophizing and neural responses to pain among persons with fibromyalgia. *Brain*. 2004;127(4):835–843.
18. Ploghaus A, Tracey I, Gaiti JS, et al. Dissociating pain from its anticipation in the human brain. *Science*. 1999;284:1979–1981.
19. Neugebauer V. The amygdala and persistent pain. *Neuroscientist*. 2004;10(3):221–234.

Address correspondence to:  
Nader E. Soliman, MD, FAAMA  
15001 Shady Grove Rd, Suite 100  
Rockville, MD 20850

E-mail: NaderSolimanMD@yahoo.com